

# Diagnosis and Treatment of Plantar Fasciitis

JAMES D. GOFF, DO, and ROBERT CRAWFORD, MD, *Summa Health System, Akron, Ohio*

Plantar fasciitis, a self-limiting condition, is a common cause of heel pain in adults. It affects more than 1 million persons per year, and two-thirds of patients with plantar fasciitis will seek care from their family physician. Plantar fasciitis affects sedentary and athletic populations. Obesity, excessive foot pronation, excessive running, and prolonged standing are risk factors for developing plantar fasciitis. Diagnosis is primarily based on history and physical examination. Patients may present with heel pain with their first steps in the morning or after prolonged sitting, and sharp pain with palpation of the medial plantar calcaneal region. Discomfort in the proximal plantar fascia can be elicited by passive ankle/first toe dorsiflexion. Diagnostic imaging is rarely needed for the initial diagnosis of plantar fasciitis. Use of ultrasonography and magnetic resonance imaging is reserved for recalcitrant cases or to rule out other heel pathology; findings of increased plantar fascia thickness and abnormal tissue signal the diagnosis of plantar fasciitis. Conservative treatments help with the disabling pain. Initially, patient-directed treatments consisting of rest, activity modification, ice massage, oral analgesics, and stretching techniques can be tried for several weeks. If heel pain persists, then physician-prescribed treatments such as physical therapy modalities, foot orthotics, night splinting, and corticosteroid injections should be considered. Ninety percent of patients will improve with these conservative techniques. Patients with chronic recalcitrant plantar fasciitis lasting six months or longer can consider extracorporeal shock wave therapy or plantar fasciotomy. (*Am Fam Physician*. 2011;84(6):676-682. Copyright © 2011 American Academy of Family Physicians.)

► **Patient information:**  
A handout on plantar fasciitis, written by the authors of this article, is provided on page 686.

Plantar fasciitis is a common cause of heel pain in adults. It is estimated that more than 1 million patients seek treatment annually for this condition, with two-thirds going to their family physician.<sup>1</sup> Plantar fasciitis is thought to be caused by biomechanical overuse from prolonged standing or running, thus creating microtears at the calcaneal entheses.<sup>1-3</sup> Some experts have deemed this condition “plantar fasciosis,” implying that its etiology is a more chronic degenerative process versus acute inflammation.<sup>2,3</sup>

## Clinical Diagnosis

Diagnosis of plantar fasciitis is based on patient history, risk factors (*Table 1*<sup>1-3</sup>), and physical examination findings. Most patients have heel pain and tightness after standing up from bed in the morning or after they have been seated for a prolonged time. Typically, the heel pain will improve with ambulation but could intensify by day’s end if the patient continues to walk or stand for a long time.

On physical examination, patients may walk with their affected foot in an equine position to avoid placing pressure on the painful heel. Palpation of the medial plantar calcaneal region will elicit a sharp, stabbing

pain<sup>2,3</sup> (*Figure 1*). Passive ankle/first toe dorsiflexion can cause discomfort in the proximal plantar fascia; it can also assess tightness of the Achilles tendon. Other causes of heel pain should be sought if history and physical examination findings are atypical for plantar fasciitis (*Table 2*).<sup>2</sup>

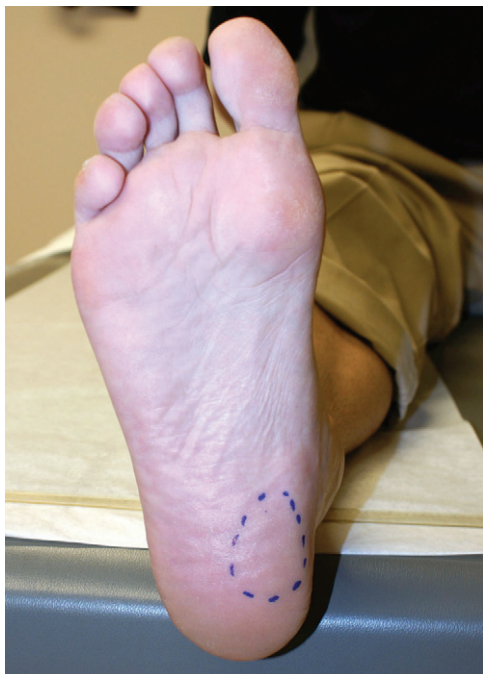## Imaging

Imaging can aid in the diagnosis of plantar fasciitis. Although not routinely needed

**Table 1. Risk Factors for Plantar Fasciitis**

Excessive foot pronation (pes planus)
Excessive running
High arch (pes cavus)
Leg length discrepancy
Obesity (body mass index greater than 30 kg per m <sup>2</sup> )
Prolonged standing/walking occupations (e.g., military personnel)
Sedentary lifestyle
Tightness of Achilles tendon and intrinsic foot muscles

*Information from references 1 through 3.*



**Figure 1.** Medial plantar region of the heel where most pain is elicited when pressure is applied during physical examination or with walking in patients with plantar fasciitis.

initially, imaging can be used to confirm recalcitrant plantar fasciitis or to rule out other heel pathology.

Plain radiography can look for bony lesions

of the foot. Subcalcaneal spur on lateral foot radiography (*Figure 2*) does not support the diagnosis of plantar fasciitis. Previous studies show that subcalcaneal spurs are also found in patients without plantar fasciitis.<sup>3,4</sup>

Ultrasonography is inexpensive and useful in ruling out soft tissue pathology of the heel. Findings that support the diagnosis of plantar fasciitis include proximal plantar fascia thickness greater than 4 mm and areas of hypoechogenicity.<sup>3,4</sup>

Magnetic resonance imaging, although expensive, is a valuable tool for assessing causes of recalcitrant heel pain.<sup>3,4</sup> Diagnostic findings include increased proximal plantar fascia thickening with increased signal intensity on T2-weighted and short tau inversion recovery images<sup>4</sup> (*Figure 3*).

### Conservative Treatments

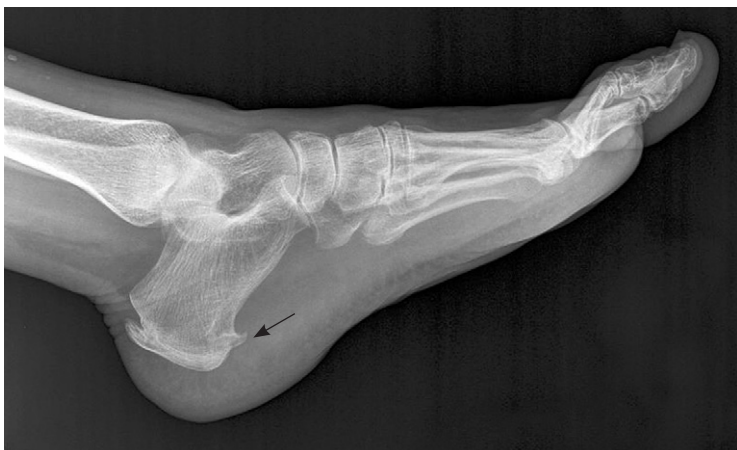Plantar fasciitis, a self-limiting condition, usually improves within one year regardless of treatment. Many patients will seek help from their physician because of disabling heel pain with activities of daily

**Table 2. Differential Diagnosis of Plantar Heel Pain**

<i>Etiology</i>	<i>Associated characteristics</i>
<b>Neurologic</b>	
Medial calcaneal and abductor digiti quinti nerve entrapment	Pain and burning sensation in the medial plantar region
Neuropathies	Diabetes mellitus, alcohol abuse, vitamin deficiency
Tarsal tunnel syndrome	Burning sensation in medial plantar region
<b>Skeletal</b>	
Acute calcaneal fracture	Direct trauma, unable to bear weight
Calcaneal apophysitis (Sever disease)	Adolescent, posterior calcaneal pain
Calcaneal stress fracture	Insidious onset of pain, repetitive loading
Calcaneal tumor	Deep bone pain
Systemic arthritides (e.g., rheumatoid arthritis, Reiter syndrome, psoriatic arthritis)	Multiple joint pain, bilateral heel pain
<b>Soft tissue</b>	
Achilles tendinitis	Posterior calcaneal/tendon pain
Heel contusion	Direct fall on heel with bone/fat pad pain
Plantar fascia rupture	Sudden plantar heel pain and ecchymosis
Posterior tibial tendinitis	Posterior medial ankle/foot pain
Retrocalcaneal bursitis	Pain in the retrocalcaneal region

*Information from reference 2.*

## Plantar Fasciitis



**Figure 2.** Lateral radiography of the foot showing a large heel spur (arrow).

living. Although several remedies exist for plantar fasciitis, there is little convincing evidence to support these various treatments. Conservative treatments usually start with patient-directed therapies and advance to physician-prescribed modalities based on how a patient's symptoms respond over weeks to months (*Figure 4*).<sup>2</sup> Within this time, 90 percent of patients will improve with conservative therapies.<sup>2,5</sup> If a patient's symptoms persist six months or longer, further invasive procedures are sometimes required.

### REST AND ANALGESIC TREATMENTS

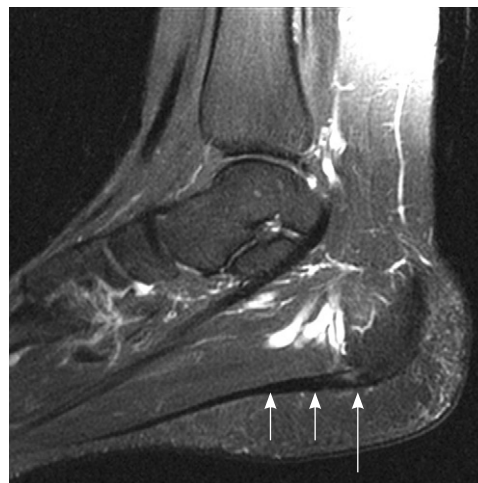
Patient-directed treatments to relieve plantar fasciitis pain consist of rest, activity modification, ice massage, and acetaminophen or nonsteroidal anti-inflammatory drugs. A small randomized, placebo-controlled study of nonsteroidal anti-inflammatory drugs to treat plantar fasciitis showed short-term improvement in pain relief and disability when accompanied by other conservative treatments.<sup>5</sup> There are few studies to support the benefit of these individual treatments used alone.

### STRETCHING AND PHYSICAL THERAPY MODALITIES

Multiple physical therapy modalities are used for the management of recalcitrant plantar fasciitis. Most therapies are used in combination; therefore, there is poor evi-

dence on which modality is best. Progressive plantar fascia and intrinsic foot muscle stretching techniques have been shown to reduce plantar fasciitis pain.<sup>6</sup> Patients can be educated on how to perform foot and ankle stretches during physician office visits. For a video of stretching exercises see: <http://www.aafp.org/afp/2011/0915/p676.html#afp20110915p676-bt1>.

Eccentric stretches, defined as exercises performed under load while the muscle is slowly lengthened (*Figure 5*), have supportive evidence in improving various tendinopathies, but have yet to be adequately studied in plantar fasciitis.<sup>7</sup> Additional prescribed physical therapy modalities, including deep myofascial massage and iontophoresis, can be performed by a physical therapist. Deep myofascial massage of the plantar fascia, manually or with instrumentation, is thought to promote healing by increasing the blood flow to the injured fascia. Most evidence for deep myofascial massage is anecdotal. Iontophoresis uses electrical pulses to cause absorption of topical medication into the soft tissue beneath the skin. In a study of 31 patients, iontophoresis with acetic acid or dexamethasone had some effectiveness in treating plantar fasciitis,<sup>8</sup> but further study is needed to substantiate the results.



**Figure 3.** Sagittal T2-weighted magnetic resonance imaging showing thickening of the plantar fascia (short arrows) and increased signal intensity (long arrow).

## Treatment Planning for Patients with Plantar Fasciitis

The rights holder did not grant the American Academy of Family Physicians the right to sublicense this material to a third party. For the missing item, see the original print version of this publication.

### ARCH SUPPORTS, HEEL CUPS, AND NIGHT SPLINTS

Foot orthotics are commonly recommended for persons with plantar fasciitis to aid in preventing overpronation of the foot and to unload tensile forces on the plantar fascia. There are many different orthotics available, including viscoelastic heel cups (*Figure 6*), prefabricated longitudinal arch supports (*Figure 7*), and custom-made full-length shoe insoles (*Figure 8*). A recent meta-analysis and comparative trial examined the effectiveness of foot orthotics in patients with plantar fasciitis and found that prefabricated and custom foot orthotics can decrease rear foot pain and improve foot function.<sup>9,10</sup> A Cochrane review found that custom foot orthotics may not reduce foot pain any more than prefabricated foot orthotics, but that when custom foot orthotics are used in conjunction with a night splint, patients may get heel pain relief.<sup>11</sup>

Night splints prevent plantar fascia contracture by keeping the foot and ankle in a neutral 90-degree position, preventing foot plantar flexion during sleep. Night splints used alone have been shown to improve plantar fasciitis pain,<sup>9,12</sup> but poor compliance because of sleep disturbance and foot discomfort has limited their long-term use. Anterior night splints (*Figure 9*) seem to be better tolerated than posterior night splints<sup>12</sup> (*Figure 10*).

Patients can purchase prefabricated night splints and arch supports from their local drug store. Physicians can have custom full-length arch support or anterior night splints made for patients by prescribing an orthotic evaluation and fitting from a local orthotist. Patients should obtain prior authorization from their insurance company before scheduling an orthotic evaluation.

Supportive arch taping, usually tried during physical therapy, may provide relief in first-step heel pain, but is inconsistent for long-term plantar fascia pain.<sup>6,13</sup>

### INJECTIONS

Corticosteroid injections are commonly used in the treatment of acute and chronic plantar fasciitis and have proven effective.

### Figure 4. Treatment planning for patients with plantar fasciitis.

Adapted with permission from Thomas JL, Christensen JC, Kravitz SR, et al.; American College of Foot and Ankle Surgeons Heel Pain Committee. The diagnosis and treatment of heel pain: a clinical practice guideline-revision 2010. *J Foot Ankle Surg.* 2010;49(3 suppl):S2.

## Plantar Fasciitis



**Figure 5.** Eccentric stretch used for plantar fasciitis.



**Figure 6.** Over-the-counter heel cup.



**Figure 7.** Over-the-counter heel (*top*) and arch (*bottom*) orthotics.



**Figure 8.** Custom-made foot orthotic.

A prospective randomized study of 100 persons with plantar fasciitis compared a variety of treatments, including autologous blood injection, lidocaine (Xylocaine) needling, triamcinolone (Kenalog) injection, and triamcinolone needling, and found superior results in both triamcinolone groups.<sup>14</sup> Possible risks associated with corticosteroid injection include fat pad atrophy and plantar fascia rupture.

In recent years, other injectable options have been used to treat plantar fasciitis. Even without the use of therapeutic medications, percutaneous fenestration (dry needling) has been shown to reduce pain in as early as four weeks.<sup>15</sup> Hyperosmolar dextrose (prolotherapy), whole blood, platelet-rich plasma, and onabotulinumtoxinA (Botox) are being investigated as treatment options. In a pilot study, a 25% dextrose/lidocaine solution was shown to improve plantar fasciitis pain in 20 persons.<sup>16</sup> Intralesional whole blood injections do not appear to be as effective as corticosteroid injections in treating plantar fasciitis.<sup>14,17</sup> Platelet-rich plasma is produced via centrifuged autologous blood.



**Figure 9.** Anterior night splint.



**Figure 10.** Posterior night splint.

## SORT: KEY RECOMMENDATIONS FOR PRACTICE

<i>Clinical recommendation</i>	<i>Evidence rating</i>	<i>References</i>
Ultrasonography and magnetic resonance imaging can be useful in diagnosing plantar fasciitis by showing increased plantar fascia thickness and abnormal tissue signal.	C	3, 4
Nonsteroidal anti-inflammatory drugs can provide short-term improvement in pain from plantar fasciitis when used with other conservative therapies.	B	5
Prefabricated and custom-made foot orthotics are effective in reducing heel pain and improving foot function in patients with plantar fasciitis.	B	9-11
The use of anterior night splints can improve plantar fasciitis pain.	B	9, 12
Corticosteroid injections can provide relief for acute and chronic plantar fasciitis.	B	14, 17
Extracorporeal shock wave therapy is a viable treatment option for chronic recalcitrant plantar fasciitis.	B	21-24

*A = consistent, good-quality patient-oriented evidence; B = inconsistent or limited-quality patient-oriented evidence; C = consensus, disease-oriented evidence, usual practice, expert opinion, or case series. For information about the SORT evidence rating system, go to <http://www.aafp.org/afpsort.xml>.*

The plasma collected is rich with platelets that release growth factors to stimulate healing in degenerative tissue. Currently, platelet-rich plasma has slight evidence to support its use for nonhealing tendinopathies.<sup>18</sup> A randomized controlled trial is underway to determine if platelet-rich plasma is effective in treating plantar fasciitis.<sup>19</sup> In a small pilot study, onabotulinumtoxinA injection was shown to relieve pain for as long as 14 weeks after injection.<sup>20</sup>

### Chronic Recalcitrant Plantar Fasciitis Treatments

#### EXTRACORPOREAL SHOCK WAVE THERAPY AND PLANTAR FASCIOTOMY

If at least six months of conservative treatment is ineffective, a trial of extracorporeal shock wave therapy or plantar fasciotomy can be considered. Extracorporeal shock wave therapy is used to promote neovascularization to aid in healing degenerative tissue found in plantar fasciitis.<sup>21</sup> Over the past decade, multiple clinical trials on the use of extracorporeal shock wave therapy for plantar fasciitis have resulted in conflicting evidence. A 2005 meta-analysis showed an improvement in morning first-step heel pain in 897 patients with plantar fasciitis, but the clinical benefit was found

to be insignificant on visual analog scales.<sup>22</sup> A 2007 systematic review concluded that extracorporeal shock wave therapy is a viable treatment option for chronic recalcitrant plantar fasciitis, but each study used different treatment protocols.<sup>21</sup> Benefits of extracorporeal shock wave therapy are that it is noninvasive and offers the hope for a faster recovery time. The adverse effects of extracorporeal shock wave therapy are pain during and after the procedure, local swelling/ecchymosis, and numbness with dysesthesia.<sup>21</sup>

Plantar fasciotomy can be performed when all conservative measures have been ineffective. In two prospective studies comparing endoscopic plantar fasciotomy with extracorporeal shock wave therapy, approximately 80 to 85 percent of patients in both groups were satisfied with the results of treatment.<sup>23,24</sup> Disadvantages of surgery include incision care, immobilization, and potential complications (e.g., arch flattening, nerve injury, calcaneal fracture, long recovery time).<sup>23,24</sup>

Video courtesy of Summa Health System, Akron, Ohio.

The authors thank Nilesh Shah, MD, and Tom Bartsokas, MD, for helping with editing; Anthony Ventimiglia, MD, for helping obtain MRI images; Yanke Bionics for helping obtain the orthotic photos; and Heather Holmes, medical librarian, for helping with the literature search.

## The Authors

**JAMES D. GOFF, DO**, is a primary care sports medicine physician at Summa Health System's Center for Sports Health in Akron, Ohio, and a clinical assistant professor for Ohio University College of Osteopathic Medicine in Athens.

**ROBERT CRAWFORD, MD**, is a primary care sports medicine fellow at the Summa Health System's Center for Sports Health.

*Address correspondence to James D. Goff, DO, Summa Health System, 3838 Massillon Rd., Ste. 350A, Uniontown, OH 44685 (e-mail: goffjd@summahealth.org). Reprints are not available from the authors.*

**Author disclosure:** No relevant financial affiliations to disclose.

## REFERENCES

- Riddle DL, Schappert SM. Volume of ambulatory care visits and patterns of care for patients diagnosed with plantar fasciitis: a national study of medical doctors. *Foot Ankle Int.* 2004;25(5):303-310.
- Thomas JL, Christensen JC, Kravitz SR, et al.; American College of Foot and Ankle Surgeons Heel Pain Committee. The diagnosis and treatment of heel pain: a clinical practice guideline-revision 2010. *J Foot Ankle Surg.* 2010;49(3 suppl):S1-S19.
- Karabay N, Toros T, Hurel C. Ultrasonographic evaluation in plantar fasciitis. *J Foot Ankle Surg.* 2007;46(6):442-446.
- McMillan AM, Landorf KB, Barrett JT, Menz HB, Bird AR. Diagnostic imaging for chronic plantar heel pain: a systematic review and meta-analysis. *J Foot Ankle Res.* 2009;2:32.
- Donley BG, Moore T, Sferra J, Gozdanovic J, Smith R. The efficacy of oral nonsteroidal anti-inflammatory medication (NSAID) in the treatment of plantar fasciitis: a randomized, prospective, placebo-controlled study. *Foot Ankle Int.* 2007;28(1):20-23.
- Hyland MR, Webber-Gaffney A, Cohen L, Lichtman PT. Randomized controlled trial of calcaneal taping, sham taping, and plantar fascia stretching for the short-term management of plantar heel pain. *J Orthop Sports Phys Ther.* 2006;36(6):364-371.
- Wasielewski NJ, Kotsko KM. Does eccentric exercise reduce pain and improve strength in physically active adults with symptomatic lower extremity tendinosis? A systematic review. *J Athl Train.* 2007;42(3):409-421.
- Osborne HR, Allison GT. Treatment of plantar fasciitis by LowDye taping and iontophoresis: short term results of a double blinded, randomised, placebo controlled clinical trial of dexamethasone and acetic acid. *Br J Sports Med.* 2006;40(6):545-549.
- Lee SY, McKeon P, Hertel J. Does the use of orthoses improve self-reported pain and function measures in patients with plantar fasciitis? A meta-analysis. *Phys Ther Sport.* 2009;10(1):12-18.
- Chia KK, Suresh S, Kuah A, Ong JL, Phua JM, Seah AL. Comparative trial of the foot pressure patterns between corrective orthotics, formthotics, bone spur pads and flat insoles in patients with chronic plantar fasciitis. *Ann Acad Med Singapore.* 2009;38(10):869-875.
- Hawke F, Burns J, Radford JA, du Toit V. Custom-made foot orthoses for the treatment of foot pain. *Cochrane Database Syst Rev.* 2008;(3):CD006801.
- Roos E, Engström M, Söderberg B. Foot orthoses for the treatment of plantar fasciitis. *Foot Ankle Int.* 2006;27(8):606-611.
- Radford JA, Landorf KB, Buchbinder R, Cook C. Effectiveness of low-Dye taping for the short-term treatment of plantar heel pain: a randomised trial. *BMC Musculoskelet Disord.* 2006;7:64.
- Kalaci A, Cakici H, Hapa O, Yanat AN, Dogramaci Y, Sevinç TT. Treatment of plantar fasciitis using four different local injection modalities: a randomized prospective clinical trial. *J Am Podiatr Med Assoc.* 2009;99(2):108-113.
- Hassan FO. Percutaneous fenestration of the antero-medial aspect of the calcaneus for resistant heel pain syndrome. *Foot Ankle Surg.* 2009;15(2):90-95.
- Ryan MB, Wong AD, Gillies JH, Wong J, Taunton JE. Sonographically guided intratendinous injections of hyperosmolar dextrose/lidocaine: a pilot study for the treatment of chronic plantar fasciitis. *Br J Sports Med.* 2009;43(4):303-306.
- Lee TG, Ahmad TS. Intralesional autologous blood injection compared to corticosteroid injection for treatment of chronic plantar fasciitis. A prospective, randomized, controlled trial. *Foot Ankle Int.* 2007;28(9):984-990.
- Sampson S, Gerhardt M, Mandelbaum B. Platelet rich plasma injection grafts for musculoskeletal injuries: a review. *Curr Rev Musculoskelet Med.* 2008;1(3-4):165-174.
- Peerbooms JC, van Laar W, Faber F, Schuller HM, van der Hoeven H, Gosens T. Use of platelet rich plasma to treat plantar fasciitis: design of a multi centre randomized controlled trial. *BMC Musculoskelet Disord.* 2010;11:69.
- Placzek R, Deuretzbacher G, Buttgerit F, Meiss AL. Treatment of chronic plantar fasciitis with botulinum toxin A: an open case series with a 1 year follow up. *Ann Rheum Dis.* 2005;64(11):1659-1661.
- Rompe JD, Furia J, Weil L, Maffulli N. Shock wave therapy for chronic plantar fasciopathy. *Br Med Bull.* 2007;81-82:183-208.
- Thomson CE, Crawford F, Murray GD. The effectiveness of extra corporeal shock wave therapy for plantar heel pain: a systematic review and meta-analysis. *BMC Musculoskelet Disord.* 2005;6:19.
- Othman AM, Ragab EM. Endoscopic plantar fasciotomy versus extracorporeal shock wave therapy for treatment of chronic plantar fasciitis. *Arch Orthop Trauma Surg.* 2010;130(11):1343-1347.
- Weil LS Jr, Roukis TS, Weil LS, Borrelli AH. Extracorporeal shock wave therapy for the treatment of chronic plantar fasciitis: indications, protocol, intermediate results, and a comparison of results to fasciotomy. *J Foot Ankle Surg.* 2002;41(3):166-172.